

---

---

# SNM Practice Guideline for Dopamine Transporter Imaging with $^{123}\text{I}$ -Ioflupane SPECT 1.0\*

David S.W. Djang<sup>1</sup>, Marcel J.R. Janssen<sup>2</sup>, Nicolaas Bohnen<sup>3</sup>, Jan Booij<sup>4</sup>, Theodore A. Henderson<sup>5</sup>, Karl Herholz<sup>6</sup>, Satoshi Minoshima<sup>7</sup>, Christopher C. Rowe<sup>8</sup>, Osama Sabri<sup>9</sup>, John Seibyl<sup>10</sup>, Bart N.M. Van Berckel<sup>11</sup>, and Michele Wanner<sup>12</sup>

<sup>1</sup>Seattle Nuclear Medicine, Seattle, Washington; <sup>2</sup>Radboud University Nijmegen Medical Centre, Nijmegen, The Netherlands; <sup>3</sup>University of Michigan Medical Center, Ann Arbor, Michigan; <sup>4</sup>Academic Medical Center, University of Amsterdam, Amsterdam, The Netherlands; <sup>5</sup>The Synaptic Space, Centennial, Colorado; <sup>6</sup>Wolfson Molecular Imaging Centre, Manchester, England; <sup>7</sup>University of Washington, Seattle, Washington; <sup>8</sup>Austin Hospital, Melbourne, Australia; <sup>9</sup>University Hospital Leipzig, Leipzig, Saxony, Germany; <sup>10</sup>Institute for Neurodegenerative Disorders, New Haven, Connecticut; <sup>11</sup>VU University Medical Center Amsterdam, Amsterdam, The Netherlands; and <sup>12</sup>University of Washington, Seattle, Washington

---

## PREAMBLE

The Society of Nuclear Medicine (SNM) is an international scientific and professional organization founded in 1954 to promote the science, technology, and practical application of nuclear medicine. Its 16,000 members are physicians, technologists, and scientists specializing in the research and practice of nuclear medicine. In addition to publishing journals, newsletters, and books, the SNM also sponsors international meetings and workshops designed to increase the competencies of nuclear medicine practitioners and to promote new advances in the science of nuclear medicine.

The SNM will periodically define new practice guidelines for nuclear medicine practice to help advance the science of nuclear medicine and to improve the quality of service to patients throughout the United States. Existing practice guidelines will be reviewed for revision or renewal, as appropriate, on their fifth anniversary or sooner, if indicated.

Each practice guideline, representing a policy statement by the SNM, has undergone a thorough consensus process in which it has been subjected to extensive review, requiring the approval of the Committee on Guidelines and SNM Board of Directors. The SNM recognizes that the safe and effective use of diagnostic nuclear medicine imaging requires specific training, skills, and techniques, as described in each document. Reproduction or modifica-

tion of the published practice guideline by those entities not providing these services is not authorized.

These guidelines are an educational tool designed to assist practitioners in providing appropriate care for patients. They are not inflexible rules or requirements of practice and are not intended, nor should they be used, to establish a legal standard of care. For these reasons and those set forth below, the SNM cautions against the use of these guidelines in litigation in which the clinical decisions of a practitioner are called into question.

The ultimate judgment regarding the propriety of any specific procedure or course of action must be made by the physician or medical physicist in light of all the circumstances presented. Thus, there is no implication that an approach differing from the guidelines, standing alone, was below the standard of care. To the contrary, a conscientious practitioner may responsibly adopt a course of action different from that set forth in the guidelines when, in the reasonable judgment of the practitioner, such course of action is indicated by the condition of the patient, limitations of available resources, or advances in knowledge or technology subsequent to publication of the guidelines.

The practice of medicine involves not only the science, but also the art, of dealing with the prevention, diagnosis, alleviation, and treatment of disease. The variety and complexity of human conditions make it impossible to always reach the most appropriate diagnosis or to predict with certainty a particular response to treatment. Therefore, it should be recognized that adherence to these guidelines will not ensure an accurate diagnosis or a successful outcome. All that should be expected is that the practitioner will follow a reasonable course of action based on current knowledge, available resources, and the needs of the patient to deliver effective and safe medical care. The sole purpose of these guidelines is to assist practitioners in achieving this objective.

---

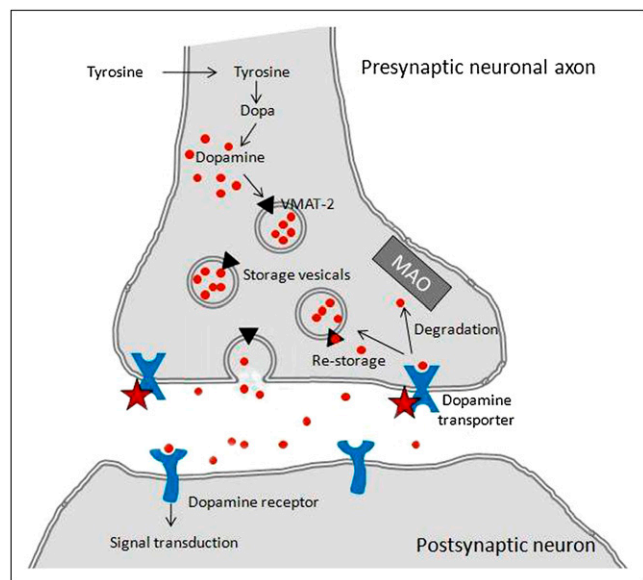
Received Nov. 11, 2011; accepted Nov. 11, 2011.  
For correspondence or reprints contact David S.W. Djang, Seattle Nuclear Medicine, 1229 Madison St., Suite 1050, Seattle, WA 98104-1377.  
E-mail: davidswdjang@gmail.com  
\*NOTE: YOU CAN ACCESS THIS GUIDELINE THROUGH THE SNM WEBSITE (<http://www.snm.org/guidelines>).  
Published online Dec. 8, 2011.  
COPYRIGHT © 2012 by the Society of Nuclear Medicine, Inc.  
DOI: 10.2967/jnumed.111.100784

## I. INTRODUCTION

*N*- $\omega$ -fluoropropyl-2 $\beta$ -carbomethoxy-3 $\beta$ -(4- $^{123}$ I-iodophenyl)nortropane ( $^{123}$ I-ioflupane) is a molecular imaging agent used to demonstrate the location and concentration of dopamine transporters (DaTs) in the synapses (Fig. 1) of striatal dopaminergic neurons. This agent has shown efficacy for detecting degeneration of the dopaminergic nigrostriatal pathway, allowing better separation of patients with essential tremor from those with presynaptic Parkinsonian syndromes, as well as differentiating between some causes of parkinsonism.

Parkinsonian syndromes are a group of diseases that share similar cardinal signs of parkinsonism, characterized by bradykinesia, rigidity, tremor at rest, and postural instability. Although the neurodegenerative condition Parkinson's disease is the most common cause of parkinsonism, numerous other etiologies can lead to a similar set of symptoms, including multiple system atrophy, progressive supranuclear palsy, corticobasal degeneration, drug-induced parkinsonism, vascular parkinsonism, and psychogenic parkinsonism. Essential tremor typically occurs during voluntary movement rather than at rest; however, some patients with essential tremor can demonstrate resting tremor, rigidity, or other isolated Parkinsonian features, mimicking other etiologies. Clinical diagnosis of parkinsonism is often straightforward, obviating additional tests in many cases. However, for incomplete syndromes, or an overlap between multiple concurrent conditions, particularly early on, an improvement in diagnostic accuracy may be possible using a test for DaT visualization (1–3).

The dopaminergic neurotransmitter system plays a vital role in parkinsonism. The nigrostriatal dopaminergic pathway can be analyzed at the striatal level, where the nigrostriatal neurons end and connect to the postsynaptic neurons using



**FIGURE 1.** Schematic of striatal dopaminergic synapse (star indicates where  $^{123}$ I-ioflupane binds).

dopamine as the neurotransmitter. Dopamine is produced in the presynaptic nerve terminals and transported into vesicles by the vesicular monoamine transporter 2 (an integral membrane protein that transports neurotransmitters such as dopamine from the cytosol into vesicles). On excitation, the dopamine from these vesicles is released into the synapse and binds to the predominantly postsynaptic dopamine receptors. On the presynaptic side, DaTs move dopamine out of the synaptic cleft and back into the nigrostriatal nerve terminals for either storage or degradation.

Imaging the integrity of the nigrostriatal dopaminergic system can improve the accuracy of diagnosing movement disorders. DaT concentrations are lower in presynaptic Parkinsonian syndromes, which include Parkinson's disease, multiple system atrophy, and progressive supranuclear palsy, and are also lower in dementia with Lewy bodies. In these cases, the decrease in DaT density is probably even greater than the decrease in intact synapses, due to compensatory downregulation of DaT in an attempt to increase synaptic dopamine concentrations. Conversely, DaT concentrations will generally be normal in parkinsonism without presynaptic dopaminergic loss, which includes essential tremor, drug-induced parkinsonism, and psychogenic parkinsonism. And in contrast to dementia with Lewy bodies, DaT concentrations are usually normal in Alzheimer's disease (3–18).

Anatomic imaging is of little help when determining the integrity of this system, but both presynaptic and postsynaptic levels can be targeted by PET and SPECT tracers. There are several PET tracers (e.g.,  $^{18}$ F-dihydroxyphenylalanine for L-dihydroxyphenylalanine decarboxylase activity;  $^{11}$ C-dihydro-tetrabenazine for vesicular monoamine transporter 2), but their use is limited primarily to scientific research. For SPECT, most tracers are cocaine analogs and target DaT (19,20). One such tracer is  $^{123}$ I-iometopane ( $^{123}$ I- $\beta$ -CIT), available largely for research (21). Similar in chemical structure,  $^{123}$ I-ioflupane ( $^{123}$ I-FP-CIT) is a SPECT tracer, licensed by the European Medicines Agency and available in Europe since 2000. In the United States,  $^{123}$ I-ioflupane was approved by the Food and Drug Administration on January 2011 and is commercially available (22). This guideline covers the indications, technical aspects, interpretation, and reporting of DaT SPECT scans with  $^{123}$ I-ioflupane and considers the work of the European Association of Nuclear Medicine (23).

## II. GOALS

The purpose of this information is to assist health care professionals in performing, interpreting, and reporting the results of DaT imaging with  $^{123}$ I-ioflupane SPECT.

## III. DEFINITIONS

See also the SNM Guideline for General Imaging.

$^{123}$ I-ioflupane is the nonproprietary name for *N*- $\omega$ -fluoropropyl-2 $\beta$ -carbomethoxy-3 $\beta$ -(4- $^{123}$ I-iodophenyl)nortropane, also abbreviated  $^{123}$ I-FP-CIT.

DaT is a transmembrane protein in the presynaptic membrane of the dopaminergic synapse that transports

dopamine from the synaptic cleft back into the presynaptic neuron.

DaT SPECT with  $^{123}\text{I}$ -ioflupane is a radionuclide imaging study that evaluates the integrity of nigrostriatal dopaminergic synapses by visualizing the presynaptic DaTs (4,6,9,19,20).

#### IV. COMMON CLINICAL INDICATIONS

Indications for  $^{123}\text{I}$ -ioflupane SPECT include, but are not limited to, the following:

##### A. Main indication

The main indication is striatal DaT visualization in the evaluation of adult patients with suspected Parkinsonian syndromes. In these patients, this test may be used to help differentiate essential tremor from tremor due to presynaptic Parkinsonian syndromes, which include Parkinson's disease, multiple system atrophy, and progressive supranuclear palsy. However, the pattern of  $^{123}\text{I}$ -ioflupane uptake cannot discriminate between these latter disorders with any high degree of accuracy (5–9,22).

##### B. Other indications

1. Early diagnosis of presynaptic Parkinsonian syndromes (12,13).
2. Differentiation of presynaptic Parkinsonian syndromes from parkinsonism without presynaptic dopaminergic loss, such as drug-induced parkinsonism or psychogenic parkinsonism (14,15).
3. Differentiation of dementia with Lewy bodies from Alzheimer's disease (16,17).

##### C. Contraindications

1. Pregnancy.
2. Inability to cooperate with SPECT or SPECT/CT brain imaging.
3. A known hypersensitivity to the active substance or to any of its excipients. An iodine allergy is, however, not a contraindication to receiving this tracer.

##### D. Relative contraindication

Breastfeeding is a relative contraindication; it is not known if  $^{123}\text{I}$ -ioflupane is excreted into human milk. For caution, if the test remains indicated, nursing women may consider pumping and discarding breast milk for at least 1 d and perhaps up to 6 d after tracer administration (22,23).

#### V. QUALIFICATIONS AND RESPONSIBILITIES OF PERSONNEL

See the SNM Guideline for General Imaging.

#### VI. PROCEDURE/SPECIFICATIONS OF THE EXAMINATION

See also the SNM Guideline for General Imaging.

#### A. Request/history

The requisition should include a brief description of symptoms and the clinical question. Information should be obtained regarding the following:

1. Past or current drug use, head trauma, stroke, psychiatric illness, epilepsy, or tumor.
2. Neurologic symptoms: kind, duration, and left or right sidedness.
3. Current medications and when last taken.
4. Patient's ability to lie still for approximately 30–45 min.
5. Prior brain imaging studies (e.g., CT, MRI, PET, and SPECT).

#### B. Patient preparation and precautions

##### 1. Prearrival

Check for medications or drugs that may alter tracer binding, and (if possible) stop such medication for at least 5 half-lives.

Cocaine, amphetamines, and methylphenidate severely decrease  $^{123}\text{I}$ -ioflupane binding to DaT. The central nervous system stimulants ephedrine and phentermine, particularly when used as tablets, may decrease  $^{123}\text{I}$ -ioflupane binding.

Bupropion, fentanyl, and some anesthetics (ketamine, phencyclidine, and isoflurane) may decrease  $^{123}\text{I}$ -ioflupane binding to DaT.

Selective serotonin reuptake inhibitors may increase binding to DaT somewhat but should not interfere with visual interpretation (24).

Cholinesterase inhibitors and neuroleptics probably do not interfere significantly with  $^{123}\text{I}$ -ioflupane binding to DaT (24).

Anti-Parkinsonian drugs (e.g., L-dihydroxyphenylalanine, dopamine agonists, monoamine oxidase B inhibitors, *N*-methyl-D-aspartate receptor blockers, amantadine, and catechol-*O*-methyltransferase inhibitors in standard dosages) do not interfere with  $^{123}\text{I}$ -ioflupane binding to DaT to any significant degree (24,25).

An extensive overview of drug influences on DaT SPECT can be found in an article by Booij and Kemp (24).

##### 2. Preinjection

To reduce exposure of the thyroid to free  $^{123}\text{I}$ , administer a single 400-mg dose of potassium perchlorate or a single dose of potassium iodide oral solution or Lugol's solution (equivalent to 100 mg of iodide) at least 1 h before the tracer injection. Avoid the use of any of these products in patients with known sensitivities (22,26). Even in the absence of a blocking agent, the radiation dose to the thyroid would be low.

#### C. Radiopharmaceutical

Licensed by the European Medicines Agency in Europe, and approved by the Food and Drug Admin-

istration in the United States,  $^{123}\text{I}$ -ioflupane is a tracer for performing DaT SPECT.  $^{123}\text{I}$ -ioflupane is a cocaine analog substance and in the United States is classified as a Schedule II controlled substance under the Controlled Substances Act. Registration with the Drug Enforcement Agency using form 222 is required to order the tracer. Alternatively, it can be ordered electronically through the Drug Enforcement Agency's Controlled Substance Ordering System (more information is available at [www.deaecom.gov](http://www.deaecom.gov)).

Appropriate physician licensure and clinic registration, in addition to secure storage, handling, and destruction practices in keeping with a Schedule II compound, are mandatory for  $^{123}\text{I}$ -ioflupane. Failure to keep accurate records or to follow proper security controls for a controlled substance may result in Drug Enforcement Agency violations and compulsory fines.

$^{123}\text{I}$ -ioflupane is delivered ready for use, although the calibrated amount of activity may need to be adjusted. The recommended dosage of  $^{123}\text{I}$ -ioflupane is 111–185 MBq (3–5 mCi), typically 185 MBq (5 mCi). It should be administered as a slow intravenous injection (over approximately 20 s), followed by a saline flush.

The effect of renal or hepatic impairment on  $^{123}\text{I}$ -ioflupane imaging has not been established. Because  $^{123}\text{I}$ -ioflupane is excreted by the kidney, patients with severe renal impairment may have increased radiation exposure and altered  $^{123}\text{I}$ -ioflupane images.

Hypersensitivity and injection site reactions have been reported. In clinical trials, the most common adverse reactions were headache, nausea, vertigo, dry mouth, and dizziness and occurred in less than 1% of subjects.

It would be reasonable to instruct the patient to increase hydration within sensible limits and to void frequently for 48 h after tracer administration to reduce the radiation dose (22,23).

$^{123}\text{I}$ -ioflupane is not indicated for use in children. Its safety and efficacy have not been established in pediatric patients.

#### D. Protocol/image acquisition

##### 1. Timing

SPECT should be started when the ratio of striatal to occipital  $^{123}\text{I}$ -ioflupane binding is stable, between 3 and 6 h after injection of the radiotracer (12,27).

It is recommended that each center use a fixed interval between tracer injection and image acquisition to optimize reproducibility and to limit inter- and intrasubject variability. Patients do not have to be kept in a dim or quiet environment.

##### 2. Positioning

Patients should be encouraged to void before scanning to avoid disturbance during image acquisition; should be positioned supine, with head centered and

as straight as possible; and should be instructed to remain still during the acquisition. An off-the-table headrest or a flexible head restraint such as a strip of tape across the chin or forehead may be used to minimize movement.

Although proper alignment with no head tilt would be preferable, patient comfort is more important than the actual orientation of the head, as long as the striatum (the caudate nucleus and putamen) and occipital cortex are in the field of view. If necessary, images can be reoriented after the acquisition.

Patients who prefer to lie with the knees slightly bent may need supporting cushions. Binding the shoulders (e.g., with a sheet) may also help to prevent movement as well as to reduce the orbital radius of the camera heads.

If a patient is not able to remain still, and if the referring physician and patient's legal representative agree, sedation with short-acting benzodiazepines can be used (and will not affect scan quality). If sedation is used and the patient traveled to the clinic by car, there should be an accompanying person to drive the patient home (22,23).

##### 3. Image acquisition

The field of view should include the entire brain, and the smallest possible rotational radius should be used. The typical radius is 11–15 cm.

The photopeak should be set to 159 keV  $\pm$  10%. Additional energy windows may be used for scatter correction purposes.

A 128  $\times$  128 matrix is recommended. Experimental studies with a striatal phantom suggest that optimal images are obtained when the selected matrix size and zoom factors give a pixel size of 3.5–4.5 mm. Slices should be 1 pixel thick.

Step-and-shoot mode with angle increments of 3° is recommended. Alternatively, continuous rotation may be used. Full 360° coverage of the head is required (i.e., 180° for each head of a dual-head camera). The number of seconds per position depends on the sensitivity of the system, but usually 30–40 s are required.

A minimum of 1.5 million total counts should be collected for optimal images, and the acquisition time will vary according to the camera specifications. It often is in the range of 30–45 min (22,23).

##### 4. Image Processing

Review of projection data in cine mode and sinograms is helpful for an initial determination of scan quality, patient motion, and artifacts. Motion correction algorithms, if available, may be used before reconstruction for minor movements, but rescanning is necessary if there is substantial head motion.

Iterative reconstruction is preferred, but filtered backprojection may be used. The reconstructed pixel size should be 3.5 to 4.5 mm with slices 1 pixel thick.

A low-pass filter (e.g., Butterworth) is recommended. Other types of filters can introduce artifacts, may affect the observed or calculated striatal binding ratio, and should be used with caution. The filter should preserve the linearity of the count rate response. Filtering includes either a 2-dimensional prefiltering of the projection data or a 3-dimensional postfiltering of the reconstructed data.

Attenuation correction is recommended. An attenuation map can be measured from a simultaneously or sequentially acquired transmission or CT scan, or can be calculated, as with a correction matrix according to Chang. The broad-beam attenuation coefficient is typically assumed to be  $0.11 \text{ cm}^{-1}$ . Some variance may occur with fan-beam collimators. Accuracy may be verified with an appropriate  $^{123}\text{I}$  phantom (28).

Images are reformatted into slices in 3 planes (axial, coronal, and sagittal). Correct reorientation makes visual interpretation easier and is crucial when semiquantification is used. Transverse slices should be parallel to a standard and reproducible anatomic orientation, such as the anterior commissure–posterior commissure line as used for brain MRI. This can be approximated by orientating the brain such that the inferior surface of the frontal lobe is level with the inferior surface of the occipital lobe. The canthomeatal plane, as routinely used for CT, is also acceptable. Activity in the striatum and the parotid glands, and the contours of the brain and the head, can usually be seen and can be used to assist realignment. A simultaneously acquired CT scan may allow more precise realignment of the head.

## 5. Semiquantification

Semiquantification is defined as the ratio of activity in a structure of interest to activity in a reference region. For semiquantification of  $^{123}\text{I}$ -ioflupane DaT SPECT, binding ratios are calculated by comparing activity in the striatum with activity in an area of low DaT concentration (usually the occipital area) using the following formula:

$$\text{Striatal binding ratio} = \frac{\text{mean counts of striatal ROI} - \text{mean counts of background ROI}}{\text{mean counts of background ROI}}$$

where ROI is region of interest.

Alternatively, volumes of interest can be used (in 3-dimensional analysis).

Semiquantification techniques roughly fall into 4 categories: classic manual ROIs, manual volumes of interest (VOIs), more advanced automated systems using VOIs, and voxel-based mathematic systems (29). The classic and most widely used method applies ROIs manually to one or more slices with the highest striatal activity. This method is simple, but interobserver variability is considerable; it is recommended that interobserver variability be reduced by rigorously standardizing realignment and using predefined ROIs

that are at least twice the full width at half maximum (30). Typically, this will result in a smallest ROI dimension of 5–7 pixels. In addition, it is recommended that at least 3 consecutive slices in the target region be used—those with the highest activity. Within the same center, it is recommended that the number of slices chosen be kept consistent (31).

Manual VOI strategies stress accurate characterization of the putamen as the most sensitive region for distinguishing normal findings from Parkinsonian syndromes. For sampling the putamen, a small VOI not encompassing the whole structure should be considered. Mid-putaminal VOIs probably offer the most accurate manual results. Automated VOI systems incorporating the whole striatum using individualized VOIs, either based on the  $^{123}\text{I}$ -ioflupane SPECT data or on a coregistered anatomic scan, produce more objective, observer-independent results and are faster although not widespread (32–35).

For both manual and automated semiquantification, the left and right striatum should be quantified separately and the caudate and putamen should be quantified separately; known anatomic lesions may influence the location of the striatal or background ROIs.

Voxel-based systems often use statistical parametric mapping that runs on a MATLAB (The MathWorks, Inc.) platform. These are widely used for scientific purposes but seem impractical for use in routine clinical practice and will not be discussed here (35,36).

## E. Interpretation

### 1. Image quality

It is important to routinely check the quality of the acquired images before interpretation. The raw projection images should be watched in cine mode or in sinogram mode to check for movement, which may be difficult to recognize in the reconstructed SPECT slices. The alignment of the head should be checked. Misalignment may create artificial asymmetry and may lead to misinterpretation of the scan.

Use of medications known to interfere with  $^{123}\text{I}$ -ioflupane binding, if present, should be considered during interpretation of images. (See section VI.B.1 [prearrival].)

### 2. Visual interpretation

Because patients usually do not become symptomatic before a substantial number of striatal synapses have degenerated, visual interpretation of the scan is usually sufficient for clinical evaluation. Several studies show excellent results with trained readers using visual interpretation only (5,37–39).

In visual interpretation, the striatal shape, extent, symmetry, and intensity differentiate normal from abnormal. The normal striata on transaxial images should look crescent- or comma-shaped and should have symmetric well-delineated borders. Abnormal

striata will have reduced intensity on one or both sides, often shrinking to a circular or oval shape.

The level of striatal activity should be compared with the background activity. Both orthogonal slices and multiple-intensity-projection images can be used. The head of the caudate and the putamen should have high contrast to the background in all scales and for patients of all ages.

Some decrease in striatal binding, in both the caudate and putamen, occurs with normal aging (~5%–7% per decade). This decrease is small in comparison to the decreases caused by disease and normally should not interfere with interpretation (40).

The left and right striata should be rather symmetric in the healthy state; mild asymmetry may occur in normals. Often, disease first becomes visible in the putamen contralateral to the neurologic signs (37).

Activity in the caudate nucleus should be compared with activity in the putamen. The putamen is usually more severely affected than the caudate nucleus (37).

Common patterns for abnormalities emerge on visual interpretation: for example, in Parkinson's disease there is usually a decrease in  $^{123}\text{I}$ -ioflupane binding in the dorsal putamen contralateral to the neurologic symptoms, progressing anteriorly and ipsilaterally over time, whereas atypical Parkinsonian syndromes tend to be more symmetric and to involve relatively more of the caudate nucleus. However, there is too much overlap between the disease patterns to allow for adequate discrimination between Parkinson's disease, multiple system atrophy, progressive supranuclear palsy, and corticobasal degeneration (5–9).

In essential tremor and in drug-induced parkinsonism,  $^{123}\text{I}$ -ioflupane binding is normal (14,39). In vascular parkinsonism,  $^{123}\text{I}$ -ioflupane binding is normal or only slightly diminished, except when an infarct directly involves a striatal structure. Even then, a deficit from an infarct often gives a “punched-out” appearance, differing in morphology and quality from a typical presynaptic Parkinsonian syndrome deficit. If clarification is needed, a recent MRI scan should be reviewed (3,41,42). In psychogenic parkinsonism, current evidence suggests that  $^{123}\text{I}$ -ioflupane binding is normal (7,15).

$^{123}\text{I}$ -ioflupane binding differentiates between Alzheimer's disease and dementia with Lewy bodies with a high degree of accuracy. Striatal binding is usually normal or only mildly diminished in Alzheimer's disease and is significantly decreased in dementia with Lewy bodies (16,17).

Image interpretation should be performed on the computer screen rather than a hard copy because the image may need to be adjusted for alignment, scaling, and color. Scans should be analyzed in both gray scale and color. Readers are recommended to select one

color scale with which to become familiar, consistent, and well-versed.

Review of any available CT head scans or MRI brain scans may give additional information. Known anatomic lesions may alter the location or shape of the striatal structures. A side-by-side reading of an equivocal scan with an MRI scan may assist in excluding or estimating vascular comorbidity.

Figures 2–5 are examples of visual interpretation (images and clinical information courtesy of John Seibyl, Institute for Neurodegenerative Disorders, New Haven, Connecticut).

### 3. Semiquantitative analysis

#### a. Overview

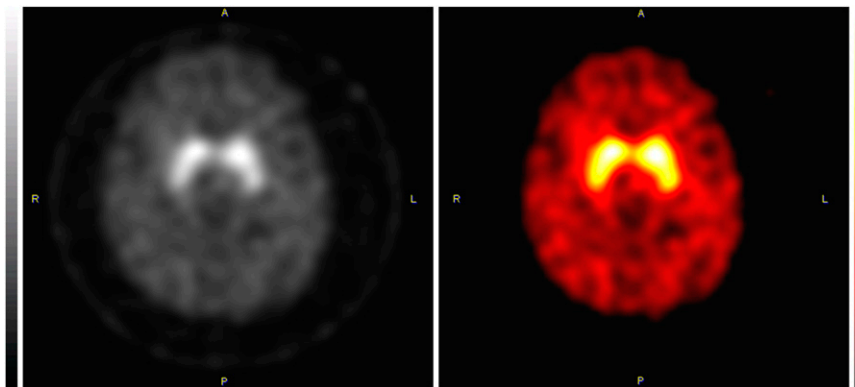
Because several studies have reported good results for diagnosis based solely on semiquantification (6,37,43), it would seem that semiquantification may yield more objective results and perhaps can benefit the inexperienced reader. However, semiquantification in those studies was done by experienced readers, and whether inexperienced readers can reproduce these results has not been validated. Despite the fact that semiquantification seems straightforward, there can be considerable interobserver variation and errors in the placement of the ROIs, or in the reorientation of the brain, that may lead to false interpretations (31). This variability may be reduced using automated systems analyzing volumes of interest in raw data (29).

Furthermore, for interpretation, semiquantitative data must be compared with a suitable database of reference values, preferably age-matched. Because many details of the camera system, the acquisition protocol, and the quantification system influence semiquantification, there is no universal cutoff value for normal vs. abnormal (44,45). Each site needs to establish its own reference range by scanning a population of healthy controls or needs to calibrate its procedure with another center that has a reference database. The latter can be done using an anthropomorphic phantom filled with different concentrations of activity. By this means, the (usually linear) relationship between measured uptake ratio and true activity can be established. If the same is done in another center, the results can be compared by calculation of the true uptake ratios from the measured uptake ratios (45).

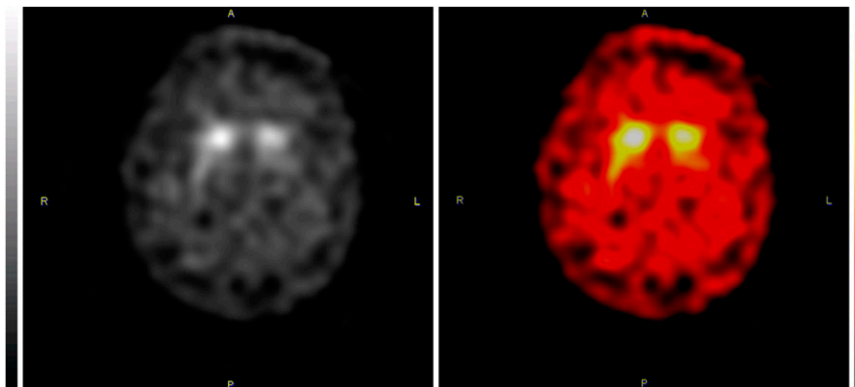
The results from a large European database of  $^{123}\text{I}$ -ioflupane scans of healthy subjects of all ages may be published in 2012 and would be useful as a reference. A similar database may be available from the Parkinson Progression Markers Initiative in the same time-frame.

Overall, there is no evidence-based answer as to whether the inexperienced reader in routine clinical settings does better with visual reading alone, with semiquantification alone, or with a combination of both.

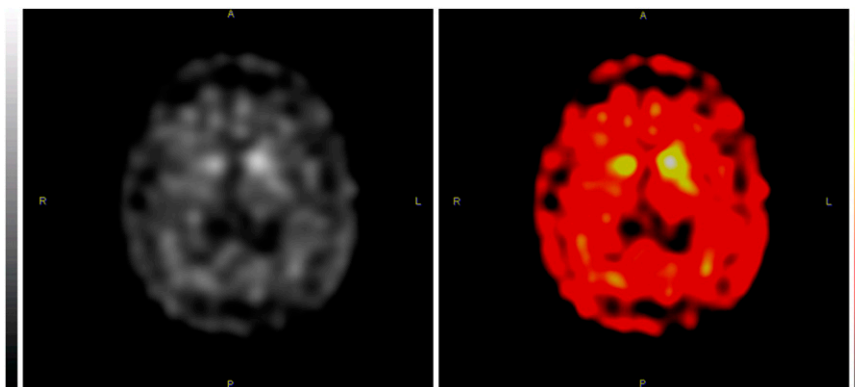
**FIGURE 2.** Normal  $^{123}\text{I}$ -ioflupane findings in 62-y-old healthy volunteer. In transaxial images, normal striatal binding is characterized by 2 symmetric crescent- or comma-shaped regions of activity. Distinction from surrounding brain tissue background is excellent.



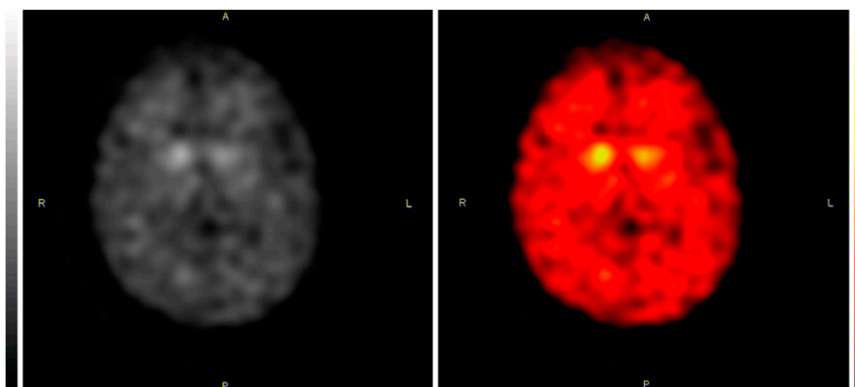
**FIGURE 3.** Abnormal  $^{123}\text{I}$ -ioflupane findings in 80-y-old man with newly diagnosed Parkinson's disease. Some early cases will demonstrate abnormality on only one side. This scan demonstrates decreases in both putamina, worse on left side. Activity is almost normal in right caudate nucleus and is mildly decreased in left caudate nucleus. Overall striatal shape on left is more oval and less crescent- or comma-shaped.



**FIGURE 4.** Abnormal  $^{123}\text{I}$ -ioflupane findings in 79-y-old man with 7-y history of Parkinson's disease. Compared with background, putamina show little tracer binding. Caudate nuclei show decreases as well, worse on right. Striatal shape is roughly oval.



**FIGURE 5.** Abnormal  $^{123}\text{I}$ -ioflupane findings in 76-y-old woman with 12-y history of Parkinson's disease. Putaminal activity is essentially absent. Markedly decreased activity is seen in caudate nuclei, worse on left. Small rounded foci are all that remains of striatal activity.



Properly performed semiquantification, with use of an extensive cross-validated age-matched set of reference values, may aid visual diagnosis. Ideally, visual interpretation and semiquantification would be complementary. When they yield varied results, the differences should be analyzed to reach a conclusion.

#### b. Potential advantages

Potential advantages of semiquantification include more objective measurement of striatal binding ratios and the ability to obtain a quantitative result that can be correlated with loss of presynaptic dopaminergic neurons. In addition, if a reference database of age-matched reference values is available, other potential advantages include earlier disease detection through detection of subtle changes, stronger interpretations in patients who are difficult to classify visually, and greater usefulness for research and multicenter studies.

#### c. Limitations

With manual ROI-based semiquantification, inter-observer variability tends to be high, and it is highest with inexperienced readers. This variability is caused largely by differences in realignment of the head, leading to artificial asymmetry or incorrect placement of the reference ROI. The greater the number of slices used in quantification, the better is the reproducibility (31).

Automated 3-dimensional VOI or voxel-based systems have better reproducibility and are faster but may not be available. They may be hampered by the lack of anatomic information in the images, especially in advanced disease, and in patients with abnormal anatomy. Automated VOI placement should therefore be checked manually (29,32–34). Of course, patients with advanced deficits should not pose a diagnostic challenge, and automated results can be verified visually.

Many factors influence quantification, such as the type of camera, its calibration, the collimators, the acquisition procedure, and the corrections (attenuation, scatter, and partial-volume effect). Therefore, comparison with reference databases from other centers, or the use of published control values, yields valid results only when the reference values were obtained with exactly the same technique or when these centers were cross-calibrated using a phantom (44,45). Age-matched controls are preferred for interpreting quantitative results.

#### d. Advice

Visual interpretation is generally sufficient for clinical interpretation (5,22,37–39).

Semiquantitative interpretation may aid visual interpretation and, if performed rigorously, may increase diagnostic accuracy (46).

Manual semiquantification should use standardized realignment of the head and the sum of at least 3 consecutive slices with standardized ROIs of at least

twice the full width at half maximum. Within the same center, a consistent number of slices should be chosen (31).

For higher reproducibility, automated 3-dimensional VOI semiquantification is preferred, especially for inexperienced readers. Placement of the VOIs should be checked visually, especially in patients with abnormal anatomy or with low uptake in the striatum.

The values of a reference population, preferably age-matched, are essential for interpretation of semiquantitative results. Reporting of the striatal binding ratio as a percentage of age-matched reference uptake should be considered. When an external reference database is used, the scanner, scanning protocol, and quantitation procedure should be calibrated with those used for the reference database with an anthropomorphic phantom with known activity concentrations (45).

## VII. DOCUMENTATION/REPORTING

See also the SNM Guideline for General Imaging.

Several items specific to <sup>123</sup>I-ioflupane SPECT should be included in the report:

### A. History

State whether the patient used interfering drugs, and if so, which drugs.

If sedation had to be performed, describe the route, dosage, and timing in relation to the scan.

### B. Technique

State the time that elapsed between tracer injection and acquisition.

State the injected radiopharmaceutical dose.

State what criteria are used for the report interpretation (e.g., visual assessment, semiquantitative analysis, or comparison to reference database).

### C. Diagnostic findings

Mention any significant scan quality limitations, such as patient motion.

Describe the subjective visual impression of striatal binding compared with background activity. Examine both the caudate nuclei and the putamina for decreased activity; note which regions, if any, appear decreased. Note any significant asymmetries; mild asymmetry may occur in healthy individuals.

If abnormalities are present, report the location and intensity of the areas of decreased activity.

If semiquantitative analysis is performed, report the values and the reference range. An age-matched reference range would be preferable.

Compare the findings with any available previous <sup>123</sup>I-ioflupane SPECT studies for that individual.



**TABLE 1**  
Radiation Dosimetry in Adults

Administered activity*		Urinary bladder wall (organ receiving largest radiation dose)		Effective dose	
MBq	mCi	mGy/MBq	rad/mCi	mSv/MBq	rem/mCi
111–185	3–5	0.054	0.20	0.021–0.024	0.078–0.09

\*Typical dose: 185 MBq (5 mCi).

Correlate the findings with relevant anatomic changes displayed on any available CT or MRI scans or with abnormal <sup>18</sup>F-FDG PET patterns.

#### D. Report conclusion

The conclusion should state whether a presynaptic dopaminergic deficit is present or absent. Abnormal findings indicate a presynaptic striatal dopaminergic deficit, which is consistent with a variety of diagnoses, including Parkinson's disease, progressive supranuclear palsy, multiple system atrophy, and dementia with Lewy bodies. Normal findings could suggest essential tremor, drug-induced parkinsonism, psychogenic parkinsonism, Alzheimer's disease, or a state of health.

For properly selected patients within the approved indication in the United States, abnormal findings would be consistent with tremor due to presynaptic Parkinsonian syndromes rather than essential tremor.

To aid the referring clinician, descriptors such as mild, moderate, or severe can be used to characterize any deficits.

When appropriate, follow-up or additional studies (<sup>18</sup>F-FDG PET, perfusion SPECT, MRI, or cardiac <sup>123</sup>I-ioflupane [MIBG]) can be recommended to clarify or confirm the suspected diagnosis. Postsynaptic D<sub>2</sub> receptor SPECT or PET may be helpful for the differential diagnosis of Parkinsonian syndromes but may have to be performed within an institutional review board–approved clinical trial.

### VIII. EQUIPMENT SPECIFICATIONS

A multidetector SPECT  $\gamma$ -camera is advised for image acquisition. A single-detector camera may provide less than optimal resolution (32). Low-energy high-resolution or low-energy ultra high-resolution parallel-hole collimators are most commonly used for brain imaging and provide acceptable images of diagnostic quality. Medium-energy collimators or all-purpose collimators are less suitable. Dedicated brain SPECT systems, collimator sets specifically adapted to the characteristics of <sup>123</sup>I, or fanbeam collimators may be preferred if available. For extrinsic uniformity calibrations, the use of a <sup>123</sup>I flood source may be more rigorous than <sup>99m</sup>Tc or <sup>57</sup>Co flood sources.

### IX. QUALITY CONTROL AND IMPROVEMENT, SAFETY, INFECTION CONTROL, AND PATIENT EDUCATION CONCERNS

See the SNM Guideline for General Imaging.

### X. RADIATION SAFETY IN IMAGING

See also the SNM Guideline for General Imaging.

Table 1 presents radiation dosimetry data in adults (22,23,47). The effective dose resulting from <sup>123</sup>I-ioflupane administration with an administered activity of 185 MBq (5 mCi) is 3.89–4.44 mSv in adults.

### ACKNOWLEDGMENTS

The Committee on SNM Guidelines consists of the following individuals: Kevin J. Donohoe, MD (Chair) (Beth Israel Deaconess Medical Center, Boston, MA); Sue Abreu, MD (Sue Abreu Consulting, Nichols Hills, OK); Helena Balon, MD (William Beaumont Hospital, Royal Oak, MI); Twyla Bartel, DO (UAMS, Little Rock, AR); Paul E. Christian, CNMT, BS, PET (Huntsman Cancer Institute, University of Utah, Salt Lake City, UT); Dominique Delbeke, MD (Vanderbilt University Medical Center, Nashville, TN); Vasken Dilsizian, MD (University of Maryland Medical Center, Baltimore, MD); Kent Friedman, MD (NYU School of Medicine, New York, NY); James R. Galt, PhD (Emory University Hospital, Atlanta, GA); Jay A. Harolds, MD (OUHSC Department of Radiological Science, Edmond, OK); Aaron Jessop, MD (UT MD Anderson Cancer Center, Houston, TX); David H. Lewis, MD (Harborview Medical Center, Seattle, WA); J. Anthony Parker, MD, PhD (Beth Israel Deaconess Medical Center, Boston, MA); James A. Ponto, RPh, BCNP (University of Iowa, Iowa City, IA); Henry Royal, MD (Mallinckrodt Institute of Radiology, St. Louis, MO); Rebecca A. Sajdak, CNMT, FSNMTS (Loyola University Medical Center, Maywood, IL); Heiko Schoder, MD (Memorial Sloan-Kettering Cancer Center, New York, NY); Barry L. Shulkin, MD, MBA (St. Jude Children's Research Hospital, Memphis, TN); Michael G. Stabin, PhD (Vanderbilt University, Nashville, TN); and Mark Tulchinsky, MD (Milton S. Hershey Med Center, Hershey, PA). Jan Booij is a consultant of GE Healthcare.

### XII. REFERENCES

1. Meara J, Bhowmick BK, Hobson P. Accuracy of diagnosis in patients with presumed Parkinson's disease. *Age Ageing*. 1999;28:99–102.
2. Hughes AJ, Ben-Shlomo Y, Daniel SE, Lees AJ. What features improve the accuracy of clinical diagnosis in Parkinson's disease: a clinicopathologic study. *Neurology*. 2001;57(suppl 3):S34–S38.
3. Marshall V, Grosset D. Role of dopamine transporter imaging in routine clinical practice. *Mov Disord*. 2003;18:1415–1423.
4. Catafau AM. Brain SPECT of dopaminergic neurotransmission: a new tool with proved clinical impact. *Nucl Med Commun*. 2001;22:1059–1060.
5. Benamer TS, Patterson J, Grosset DG, et al. Accurate differentiation of parkinsonism and essential tremor using visual assessment of [<sup>123</sup>I]FP-CIT SPECT imaging. *Mov Disord*. 2000;15:503–510.
6. Booij J, Habraken JB, Bergmans P, et al. Imaging of dopamine transporters with iodine-123-FP-CIT SPECT in healthy controls and patients with Parkinson's disease. *J Nucl Med*. 1998;39:1879–1884.

7. Scherfler C, Schwarz J, Antonini A, et al. Role of DAT-SPECT in the diagnostic work up of parkinsonism. *Mov Disord*. 2007;22:1229–1238.
8. Vlaar AM, de Nijs T, Kessels AG, et al. Diagnostic value of <sup>123</sup>I-ioflupane and <sup>123</sup>I-iodobenzamide SPECT scans in 248 patients with parkinsonian syndromes. *Eur Neurol*. 2008;59:258–266.
9. Vlaar AM, van Kroonenburgh MJ, Kessels AG, Weber WE. Meta-analysis of the literature on diagnostic accuracy of SPECT in parkinsonian syndromes. *BMC Neurol*. 2007;7:27.
10. Benamer HT, Patterson J, Wyper DJ, Hadley DM, Macphee GJ, Grosset DG. Correlation of Parkinson's disease severity and duration with <sup>123</sup>I-FP-CIT SPECT striatal uptake. *Mov Disord*. 2000;15:692–698.
11. Pirker W. Correlation of dopamine transporter imaging with parkinsonian motor handicap: how close is it? *Mov Disord*. 2003;18(suppl. 7):S43–S51.
12. Booij J, Tissingh G, Boer GJ, et al. [<sup>123</sup>I]FP-CIT SPECT shows a pronounced decline of striatal dopamine transporter labelling in early and advanced Parkinson's disease. *J Neurol Neurosurg Psychiatry*. 1997;62:133–140.
13. Ponsen MM, Stoffers D, Wolters ECh, Booij J, Berendse HW. Olfactory testing combined with dopamine transporter imaging as a method to detect prodromal Parkinson's disease. *J Neurol Neurosurg Psychiatry*. 2010;81:396–399.
14. Lorberboym M, Treves TA, Melamed E, Lampl Y, Hellmann M, Djaldetti R. [<sup>123</sup>I]-FP/CIT SPECT imaging for distinguishing drug-induced parkinsonism from Parkinson's disease. *Mov Disord*. 2006;21:510–514.
15. Felicio AC, Godeiro-Junior C, Moriyama TS, et al. Degenerative parkinsonism in patients with psychogenic parkinsonism: a dopamine transporter imaging study. *Clin Neurol Neurosurg*. 2010;112:282–285.
16. McKeith I, O'Brien J, Walker Z, et al. Sensitivity and specificity of dopamine transporter imaging with <sup>123</sup>I-FP-CIT SPECT in dementia with Lewy bodies: a phase III, multicentre study. *Lancet Neurol*. 2007;6:305–313.
17. Walker Z, Jaros E, Walker RW, et al. Dementia with Lewy bodies: a comparison of clinical diagnosis, <sup>123</sup>I-FP-CIT single photon emission computed tomography imaging and autopsy. *J Neurol Neurosurg Psychiatry*. 2007;78:1176–1181.
18. Carroll FI, Scheffel U, Dannals RF, Boja JW, Kuhar MJ. Development of imaging agents for the dopamine transporter. *Med Res Rev*. 1995;15:419–444.
19. Günther I, Hall H, Hallidin C, Swahn CG, Farde L, Sedvall G. [<sup>125</sup>I] beta-CIT-FE and [<sup>125</sup>I] beta-CIT-FP are superior to [<sup>125</sup>I] beta-CIT for dopamine transporter visualization: autoradiographic evaluation in the human brain. *Nucl Med Biol*. 1997;24:629–634.
20. Abi-Dargham A, Gandelman MS, DeErasquin GA, et al. SPECT imaging of dopamine transporters in human brain with iodine-123-fluoroalkyl analogs of beta-CIT. *J Nucl Med*. 1996;37:1129–1133.
21. Iometopane: <sup>123</sup>I beta-CIT, Dopascan injection, GPI 200, RTI 55. *Drugs R D*. 2003;4:320–322.
22. DaTscan prescribing information. Available at: [http://us.datscan.com/wp-content/themes/main\\_site/pdf/prescribing-information.pdf](http://us.datscan.com/wp-content/themes/main_site/pdf/prescribing-information.pdf). Accessed October 14, 2011.
23. Darcourt J, Booij J, Tatsch K, et al. EANM procedure guidelines for brain neurotransmission SPECT using <sup>123</sup>I-labelled dopamine transporter ligands, version 2. *Eur J Nucl Med Mol Imaging*. 2010;37:443–450.
24. Booij J. [<sup>123</sup>I]FP-CIT SPECT: potential effects of drugs. *Eur J Nucl Med Mol Imaging*. 2008;35:424–438.
25. Schillaci O, Pierantozzi M, Filippi L, et al. The effect of levodopa therapy on dopamine transporter SPECT imaging with <sup>123</sup>I-FP-CIT in patients with Parkinson's disease. *Eur J Nucl Med Mol Imaging*. 2005;32:1452–1456.
26. Giammarile F, Chiti A, Lassmann M, Brans B, Flux G. EANM procedure guidelines for <sup>131</sup>I-meta-iodobenzylguanidine (<sup>131</sup>I-mIBG) therapy. *Eur J Nucl Med Mol Imaging*. 2008;35:1039–1047.
27. Booij J, Hemelaar J, Speelman J, de Bruin K, Janssen A, van Royen E. One-day protocol for imaging of the nigrostriatal pathway in Parkinson's disease by [<sup>123</sup>I] FPCIT SPECT. *J Nucl Med*. 1999;40:753–761.
28. Morano GN, Seibyl JP. Technical overview of brain SPECT imaging: improving acquisition and processing of data. *J Nucl Med Technol*. 2003;31:191–195.
29. Badiavas K, Molyvda E, Iakovou I, Tzolaki M, Psarrakos K, Karatzas N. SPECT imaging evaluation in movement disorders: far beyond visual assessment. *Eur J Nucl Med Mol Imaging*. 2011;38:764–773.
30. Habraken JB, Booij J, Slomka P, et al. Quantification and visualization of defects of the functional dopaminergic system using an automatic algorithm. *J Nucl Med*. 1999;40:1091–1097.
31. Linke R, Gostomzyk J, Hahn K, Tatsch K. [<sup>123</sup>I]IPT binding to the presynaptic dopamine transporter: variation of intra- and interobserver data evaluation in parkinsonian patients and controls. *Eur J Nucl Med*. 2000;27:1809–1812.
32. Koch W, Radau PE, Hamann C, Tatsch K. Clinical testing of an optimized software solution for an automated, observer-independent evaluation of dopamine transporter SPECT studies. *J Nucl Med*. 2005;46:1109–1118.
33. Calvini P, Rodriguez G, Inguglia F, Mignone A, Guerra UP, Nobili F. The basal ganglia matching tools package for striatal uptake semi-quantification: description and validation. *Eur J Nucl Med Mol Imaging*. 2007;34:1240–1253.
34. Morton RJ, Guy MJ, Clauss R, Hinton PJ, Marshall CA, Clarke EA. Comparison of different methods of DaTSCAN quantification. *Nucl Med Commun*. 2005;26:1139–1146.
35. Zubal IG, Early M, Yuan O, Jennings D, Marek K, Seibyl JP. Optimized, automated striatal uptake analysis applied to SPECT brain scans of Parkinson's disease patients. *J Nucl Med*. 2007;48:857–864.
36. Kas A, Payoux P, Habert MO, et al. Validation of a standardized normalization template for statistical parametric mapping analysis of <sup>123</sup>I-FP-CIT images. *J Nucl Med*. 2007;48:1459–1467.
37. Tissingh G, Booij J, Bergmans P, et al. Iodine-123-N-omega-fluoropropyl-2β-carbomethoxy-3β-(4-iodophenyl)tropane SPECT in healthy controls and early-stage, drug-naïve Parkinson's disease. *J Nucl Med*. 1998;39:1143–1148.
38. Catafau AM, Tolosa E. DaTSCAN Clinically Uncertain Parkinsonian Syndromes Study Group. Impact of dopamine transporter SPECT using <sup>123</sup>I-ioflupane on diagnosis and management of patients with clinically uncertain parkinsonian syndromes. *Mov Disord*. 2004;19:1175–1182.
39. Marshall VL, Reininger CB, Marquardt M, et al. Parkinson's disease is over-diagnosed clinically at baseline in diagnostically uncertain cases: a 3-year European multicenter study with repeat [<sup>123</sup>I]FP-CIT SPECT. *Mov Disord*. 2009;24:500–508.
40. Lavalaye J, Booij J, Reneman L, Habraken JB, van Royen EA. Effect of age and gender on dopamine transporter imaging with [<sup>123</sup>I]FP-CIT SPET in healthy volunteers. *Eur J Nucl Med*. 2000;27:867–869.
41. Lorberboym M, Djaldetti R, Melamed E, Sadeh M, Lampl Y. <sup>123</sup>I-FP-CIT SPECT imaging of dopamine transporters in patients with cerebrovascular disease and clinical diagnosis of vascular parkinsonism. *J Nucl Med*. 2004;45:1688–1693.
42. Gerschlagner W, Bencsits G, Pirker W, et al. [<sup>123</sup>I]beta-CIT SPECT distinguishes vascular parkinsonism from Parkinson's disease. *Mov Disord*. 2002;17:518–523.
43. Seibyl JP, Marek K, Sheff K, et al. Iodine-123-beta-CIT and iodine-123-FPCIT SPECT measurement of dopamine transporters in healthy subjects and Parkinson's patients. *J Nucl Med*. 1998;39:1500–1508.
44. Dickson JC, Tossici-Bolt L, Sera T, et al. The impact of reconstruction method on the quantification of DaTSCAN images. *Eur J Nucl Med Mol Imaging*. 2010;37:23–35.
45. Koch W, Radau PE, Munzing W, Tatsch K. Cross-camera comparison of SPECT measurements of a 3-D anthropomorphic basal ganglia phantom. *Eur J Nucl Med Mol Imaging*. 2006;33:495–502.
46. Jennings DL, Seibyl JP, Oakes D, Eberly S, Murphy J, Marek K. (<sup>123</sup>I) beta-CIT and single-photon emission computed tomographic imaging vs clinical evaluation in parkinsonian syndrome: unmasking an early diagnosis. *Arch Neurol*. 2004;61:1224–1229.
47. Booij J, Busemann Sokole E, Stabin MG, Janssen AG, de Bruin K, van Royen E. Human biodistribution and dosimetry of [<sup>123</sup>I]FP-CIT: a potent radioligand for imaging of dopamine transporters. *Eur J Nucl Med*. 1998;25:24–30.

## XI. APPROVAL

This Practice Guideline was approved by the Board of Directors of the SNM on October 26, 2011.